

Ischemic Gastropathy Treated with Celiac Artery Revascularization

Jeff Anucha¹, Jonathan Pinto², Joan Culpepper-Morgan², Alvaro Genao², Neil Resnick³

1. Internal Medicine, Columbia University School of Physicians and Surgeons at Harlem Hospital Center, New York, USA 2. Internal Medicine: Gastroenterology, Columbia University School of Physicians and Surgeons at Harlem Hospital Center, New York, USA 3. Radiology, Columbia University School of Physicians and Surgeons at Harlem Hospital Center, New York, USA

Corresponding author: Jeff Anucha, anuchaj@nychhc.org

Abstract

Ischemic gastropathy is an uncommon diagnosis due to extensive arterial collaterals that supply the stomach. The mucosal integrity of the stomach is dependent upon this redundant circulation. Hence, its diagnosis is infrequently entertained in patients presenting with an upper gastrointestinal (GI) bleed. Herein, we report a case of a 76-year-old woman with hypertension, hyperlipidemia, and chronic kidney disease on dialysis who developed an upper GI bleed after becoming septic and hypotensive.

Categories: Internal Medicine, Radiology, Gastroenterology

Keywords: stomach, ischemia, celiac artery stenosis, upper gi bleed, ir-guided stenting

Introduction

The stomach has a rich and redundant blood supply and is the only organ to receive arterial supply from all three branches of the celiac trunk. This is achieved through five major direct arterial sources, which are the right and left gastric, the right and left gastroepiploic, and the short gastric arteries. These form a complex and extensive plexus of collaterals that makes the stomach less prone to ischemic injury [1-2]. The mucosal integrity of the stomach is dependent upon this redundant circulation as well. Ischemic gastropathy as a direct result of mesenteric ischemia has been reported but is an uncommon diagnosis; hence, it is rarely entertained in patients presenting with an upper gastrointestinal (GI) bleed. We report a case of a 76-year-old woman with hypertension, hyperlipidemia, and chronic kidney disease on dialysis who developed an upper gastrointestinal bleed after she became septic and hypotensive.

Part of this article has been presented earlier (Pinto J, Culpepper-Morgan J, Anucha JC, Genao A, Resnick N. P2602 - A rare case of severe ischemic gastropathy causing upper GI bleed. ACG 2018 Annual Scientific Meeting Abstracts. American College of Gastroenterology; <https://eventscribe.com/2018/ACG/ajaxcalls/PosterInfo.asp?PosterID=161883&efp=RFNSWFFHSFY2NDI0&rnd=0.604323>).

Received 09/16/2019
Review began 09/19/2019
Review ended 10/17/2019
Published 10/21/2019

© Copyright 2019

Anucha et al. This is an open access article distributed under the terms of the Creative Commons Attribution License CC-BY 3.0., which permits unrestricted use, distribution, and reproduction in any medium, provided the original author and source are credited.

Case Presentation

A 76-year-old woman with hypertension, hyperlipidemia, and chronic kidney disease presented with acute shortness of breath. She was tachycardic, tachypneic, and hypotensive on exam, with expiratory wheezes and abdominal distention. Laboratory findings included elevated lactate, metabolic acidosis, leukocytosis of 22 K/uL, and hemoglobin of 10.7 g/dl. She was managed for acute respiratory failure and septic shock. Despite the treatment of her sepsis, lactic acidosis persisted.

An abdominal computerized tomography (CT), which was obtained to evaluate for ongoing abdominal distention, revealed pneumatosis intestinalis (Figure 1).

How to cite this article

Anucha J, Pinto J, Culpepper-Morgan J, et al. (October 21, 2019) Ischemic Gastropathy Treated with Celiac Artery Revascularization. Cureus 11(10): e5949. DOI 10.7759/cureus.5949

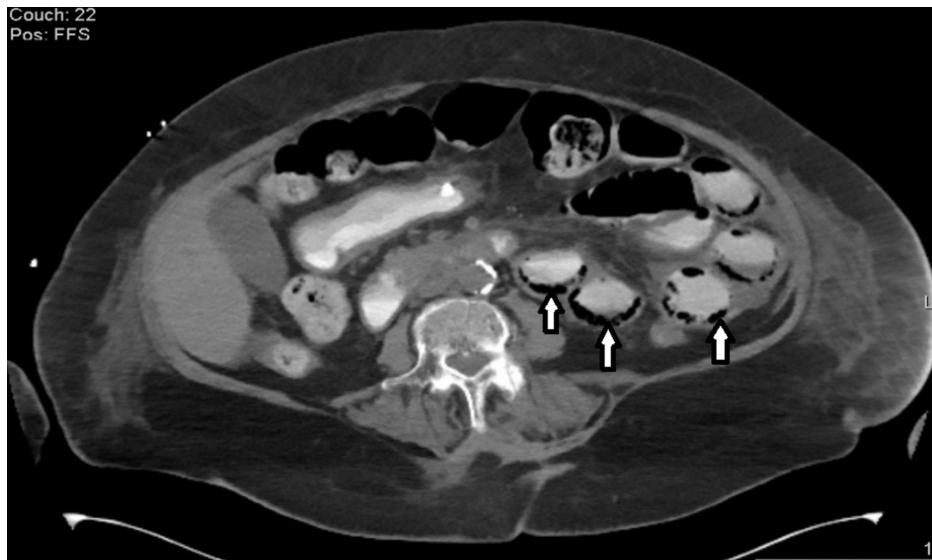

FIGURE 1: Pneumatosis intestinalis; air within the bowel wall (arrows)

Metronidazole intravenous (IV) was then started for the management of gas-forming organisms, which led to an immediate improvement in leukocytes from 24 K/uL to 8.6 K/uL. The patient developed melena and anemia (Hgb 6.4g/dl) afterwards. Esophagogastroduodenoscopy (EGD) revealed extensive shallow ischemic ulcers involving most of the anterior gastric wall and denuded duodenal mucosa (Figure 2).

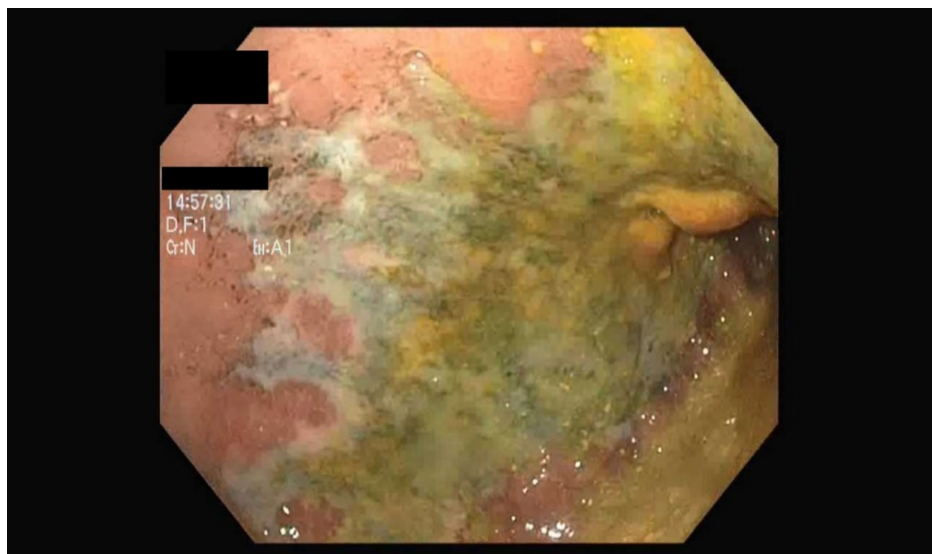


FIGURE 2: Shallow ischemic anterior gastric ulcer

Subsequent CT angiography of the abdomen showed marked atherosclerotic plaques causing high-grade stenosis of the celiac axis, lesser stenosis of the superior mesenteric artery, and complete resolution of pneumatosis intestinalis (Figure 3).

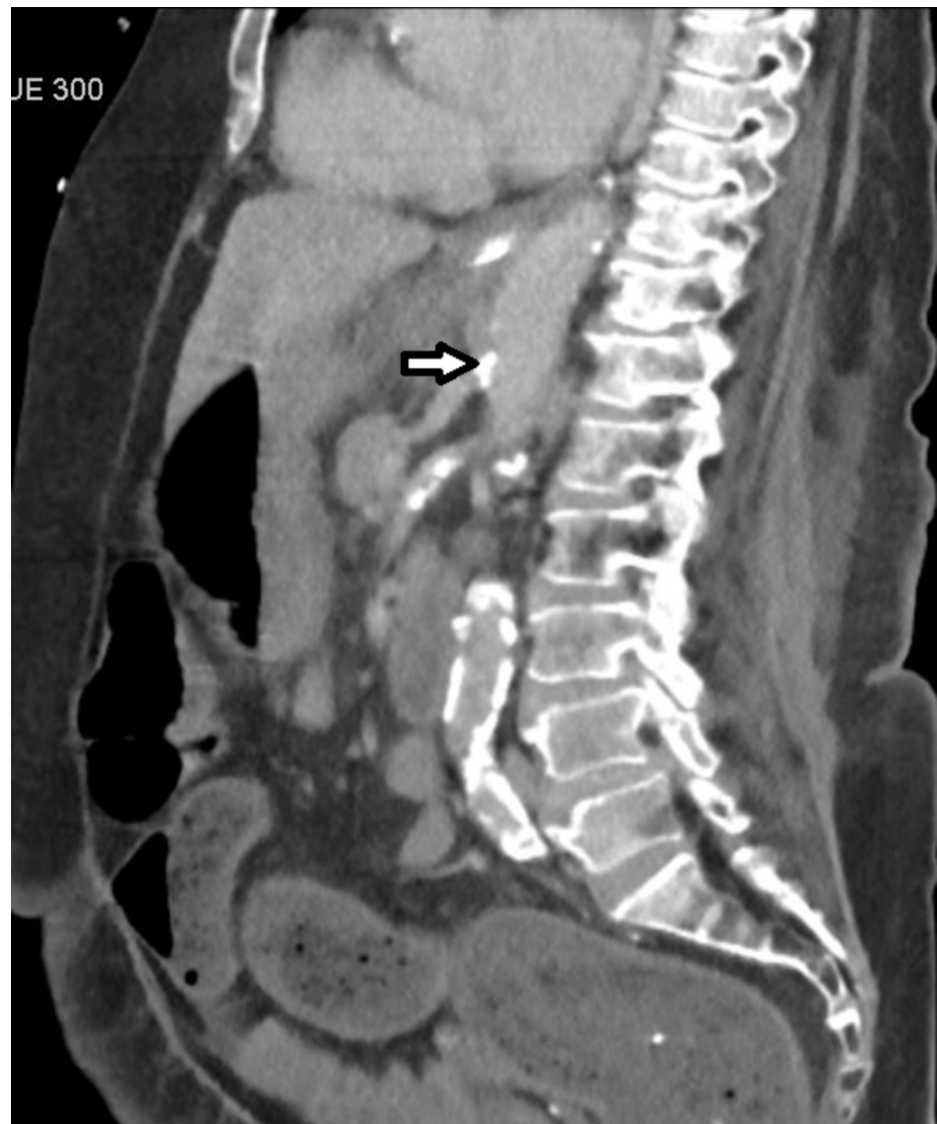

FIGURE 3: Atherosclerotic plaque within the celiac artery (arrow) and SMA causing high-grade stenosis

SMA: superior mesenteric artery

An interventional radiology (IR)-guided stent was placed across the celiac artery with successful reperfusion confirmed by fluoroscopy. Serum lactate levels rapidly normalized and a repeat EGD three weeks later showed near-complete resolution of gastric ulcers (Figure 4).

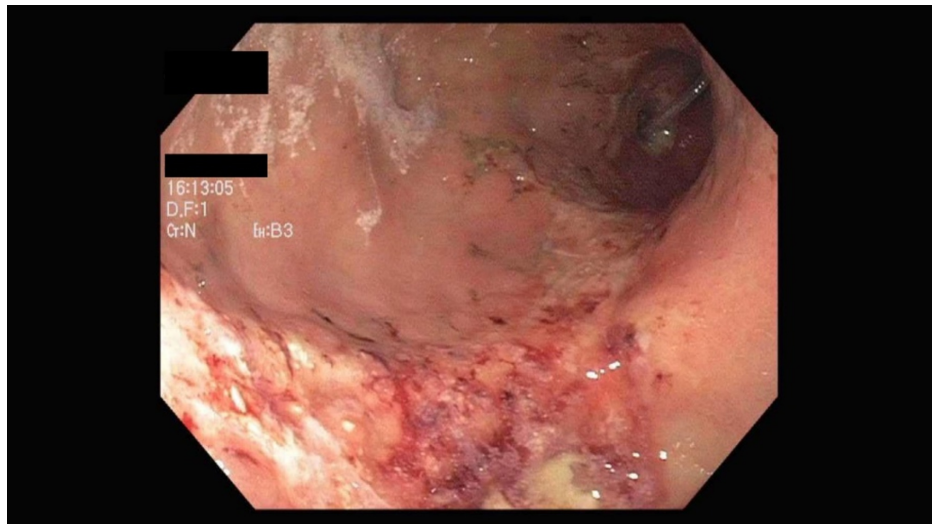


FIGURE 4: Resolution of the ischemic gastric ulcer after celiac artery stenting

Discussion

Ischemic gastropathy is a rare cause of upper GI bleeding because of an extensive network of vascular collaterals that supplies the stomach wall [1-2]. Although stenosis of the celiac trunk alone may be asymptomatic, concomitant superior mesenteric artery (SMA) stenosis may result in ischemic lesions in the stomach wall [3-5]. Clinical manifestations can include pain, nausea, vomiting, and bleeding. Gastric ischemia may be secondary to systemic hypoperfusion in the setting of shock, local splanchnic vessel stenosis, or thrombosis. Subsequent ischemia leads to gastric mucosal barrier dysfunction, accumulation of gastric acid, and eventual ulceration.

There were several predisposing risk factors to gastric ischemia in our patient, including diabetes, hypertension, and hypercholesterolemia [6]. Episodes of global hypoperfusion from sepsis may have contributed to a low flow state as well. She was on diuretics, which has been reported as a possible contributing factor, as well as intermittent hemodialysis, which has been shown to cause accelerated rates of atherosclerotic plaques [7-8]. In previous case reports reviewed, the diagnosis of gastric ischemia was often delayed because of the time spent on eliminating more common conditions, whilst a lack of response to maximal antacid therapy was observed [9-11]. For the gastrointestinal endoscopist, there should be a high index of suspicion when there are gastric ulcers in patients at risk for vascular disease [12].

The presence of SMA stenosis likely also contributed to small bowel ischemia, resulting in pneumatosis intestinalis. Correction of her underlying sepsis led to an improvement of bowel ischemia findings on follow-up CT of the abdomen.

While ischemia secondary to transient low flow states may be managed conservatively with bowel rest and broad-spectrum antibiotics, definitive recanalization of the celiac trunk may be required when high-grade stenosis is present. This can be achieved either surgically or via percutaneous transluminal intervention, with the latter preferred in high-risk patients as in our case.

Conclusions

Although exceedingly rare, ischemic gastropathy can occur and is potentially treatable with carefully selected revascularization therapy in high-risk patients.

Additional Information

Disclosures

Human subjects: Consent was obtained by all participants in this study. **Conflicts of interest:** In compliance with the ICMJE uniform disclosure form, all authors declare the following: **Payment/services info:** All authors have declared that no financial support was received from any organization for the submitted work. **Financial relationships:** All authors have declared that they have no financial relationships at present or within the previous three years with any organizations that might have an interest in the submitted work. **Other relationships:** All authors have declared that there are no other relationships or activities that could appear to have influenced the submitted work.

References

1. Brown RB, Derr JWM: Arterial blood supply of the human stomach . Arch Surg. 1952, 64:616-621. [10.1001/archsurg.1952.01260010634011](https://doi.org/10.1001/archsurg.1952.01260010634011)
2. Lanciault G, Jacobson ED: The gastrointestinal circulation. Gastroenterology. 1976, 71:851-873.
3. Mercogliano G, Tully O, Schmidt D: Gastric ischemia treated with superior mesenteric artery revascularization. Clin Gastroenterol Hepatol. 2007, 5:A26. [10.1016/j.cgh.2007.02.007](https://doi.org/10.1016/j.cgh.2007.02.007)
4. Richieri JP, Pol B, Payan MJ: Acute necrotizing ischemic gastritis: clinical, endoscopic and histopathologic aspects. Gastrointest Endosc. 1998, 48:210-212. [10.1016/s0016-5107\(98\)70168-3](https://doi.org/10.1016/s0016-5107(98)70168-3)
5. Brandt LS, Boley SJ: AGA technical review on intestinal ischemia . Gastroenterology. 2000, 118:954-968. [10.1016/s0016-5085\(00\)70183-1](https://doi.org/10.1016/s0016-5085(00)70183-1)
6. Singh R, Devi S, Gollen R: Role of free radical in atherosclerosis, diabetes and dyslipidaemia: larger-than-life. Diabetes Metab Res Rev. 2015, 31:113-126. [10.1002/dmrr.2558](https://doi.org/10.1002/dmrr.2558)
7. Richieri JP, Pol B, Payan MJ: Acute necrotizing ischemic gastritis: clinical, endoscopic and histopathologic aspects. Gastrointest Endosc. 1998, 48:210-212. [10.1016/s0016-5107\(98\)70168-3](https://doi.org/10.1016/s0016-5107(98)70168-3)
8. Collado S, Coll E, Nicolau C, Pons M, Cruzado JM, Pascual J, Cases A: Carotid atherosclerotic disease predicts cardiovascular events in hemodialysis patients: a prospective study. PLoS One. 2015, 2015:0127344. [10.1371/journal.pone.0127344](https://doi.org/10.1371/journal.pone.0127344)
9. Quentin V, Dib N, Thouveny F, L'Hoste P, Croue A, Boyer J: Chronic ischemic gastritis: case report of a difficult diagnosis and review of the literature. Endoscopy. 2006, 38:529-532. [10.1055/s-2006-925228](https://doi.org/10.1055/s-2006-925228)
10. Haberer J, Trivedi N, Kohlwes J, Tierney L: Clinical problem-solving. A gut feeling. New Eng J Med. 2003, 349:73-78. [10.1056/NEJMcps030332](https://doi.org/10.1056/NEJMcps030332)
11. De Luca L, Ricciardiello L, Modugno P: Lethal nature of ischemic gastropathy: a case report of celiomesenteric vascular insufficiency. Clin J Gastroenterol. 2011, 4:60-63. [10.1007/s12328-010-0190-9](https://doi.org/10.1007/s12328-010-0190-9)
12. Moawad J, McKinsey JF, Wyble CW, Bassiouny HS, Schwartz LB, Gewertz BL: Current results of surgical therapy for chronic mesenteric ischemia. Arch Surg. 1997, 132:613-619. [10.1001/archsurg.1997.01430300055012](https://doi.org/10.1001/archsurg.1997.01430300055012)