

# Cavernous Hemangioma in the Parotid Gland of an Adult: A Case Report and Review of Literature

Farhan M. Alanazi<sup>1,2</sup>, Saeed Alqahtani<sup>1</sup>, Sultan H. Alruwaili<sup>3</sup>, Abdullah A. Alzamil<sup>4</sup>, Fareed R. AlGhamdi<sup>1</sup>

Review began 01/03/2024

Review ended 01/10/2024

Published 01/15/2024

© Copyright 2024

Alanazi et al. This is an open access article distributed under the terms of the Creative Commons Attribution License CC-BY 4.0., which permits unrestricted use, distribution, and reproduction in any medium, provided the original author and source are credited.

1. Otolaryngology-Head and Neck Surgery, Prince Sultan Military Medical City, Riyadh, SAU 2. Otolaryngology-Head and Neck Surgery, Prince Mohammed Medical City, Jouf, SAU 3. Medicine, Jouf College of Medicine, Jouf, SAU 4. Medicine and Surgery, Unaizah College of Medicine, Unaizah, SAU

**Corresponding author:** Farhan M. Alanazi, alenazifarhan1993@gmail.com

---

---

## Abstract

Hemangiomas are benign vascular tumors and are classified into cavernous, capillary, and mixed, with the head and neck area as the most common site. Hemangiomas are common in pediatrics and rare in adults. Diagnosing cavernous hemangioma is challenging and requires a complete history, proper physical examination, and several radiological modalities to improve diagnostic accuracy because it is uncommon in adults. Herein, we present a case of a 66-year-old female Saudi patient with cavernous hemangioma from the diagnosis until the surgical treatment. No previous studies are reported in Saudi Arabia and this is a rare presentation of cavernous hemangioma at this age. Cavernous hemangioma in the parotid gland in adults is uncommon and is difficult to diagnose. Therefore, a thorough physical examination and several radiological modalities are required to improve diagnostic accuracy. The most effective treatment of cavernous hemangioma in adults is surgical resection.

---

**Categories:** Otolaryngology

**Keywords:** mass, vascular tumors, parotid gland, salivary glands, hemangiomas

## Introduction

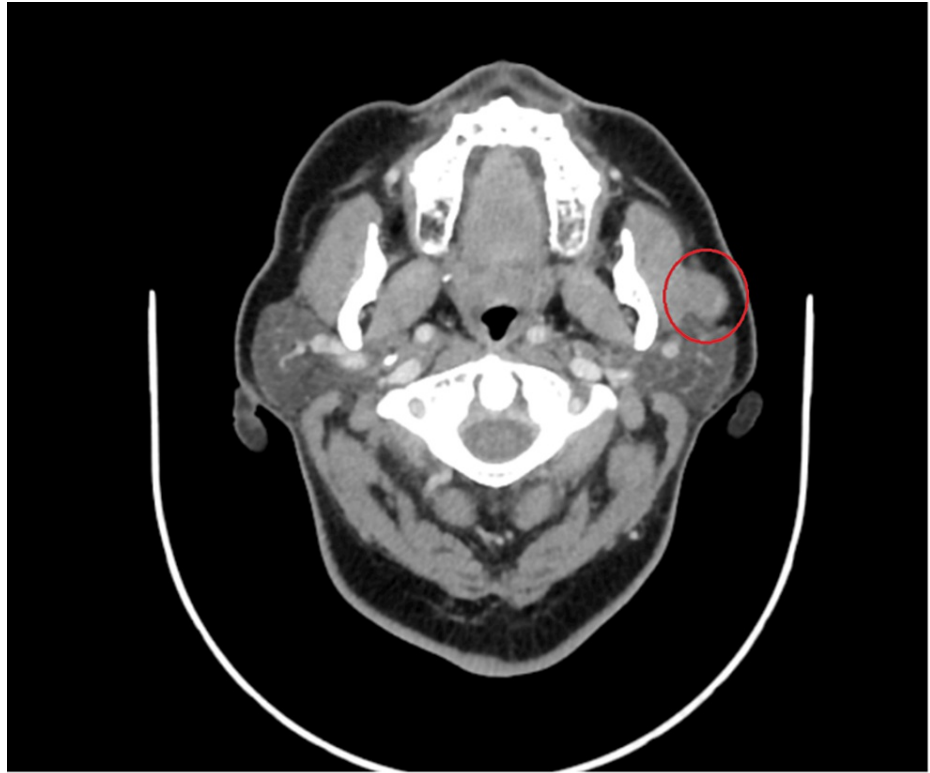Hemangiomas are benign vascular tumors caused by increased endothelial cell proliferation and turnover [1] and are categorized into cavernous, capillary, and mixed. Hemangiomas can occur anywhere on the body, with 65% of cases starting in the head and neck areas. The most commonly impacted structure is the salivary glands, with the parotid gland accounting for 80%-85% of all cases [2-4]. However, adult hemangiomas in the parotid gland only comprise 0.4%-0.6% of the total parotid gland tumors [2-4]. Typically, parotid hemangioma affects children under the age of one year. It comprises 50% of all parotid gland tumors and is characterized by rapid development and progression between the ages of six and eight months, followed by an involution period in the first decade [3,5]. Conversely, parotid hemangioma is uncommon in adults and does not regress [3,4,6].

## Case Presentation

A 66-year-old female with diabetes mellitus and hypertension presented in our clinic complaining of left pre-auricular swelling for >one year in a stable size. She denied any history of pain, numbness, or facial weakness, as well as night sweating, fever, or weight loss. Local examination revealed a non-fixed pre-auricular mass, 1 × 1 cm in size, with firm, non-tender, and well-defined borders. Head and neck examination revealed no palpable lymph nodes and facial nerves were bilaterally intact. Flexible nasal endoscopy revealed bilateral hypertrophied turbinate, clear nasopharyngeal cavity with no masses, and clear bilateral mobile vocal cords. The parotid gland ultrasonography revealed a focal-shaped hypoechoic well-demarcated lesion within the internal focus of calcification seen superficial to the left masseter muscle closely anterior to the left parotid but looks extra-parotid, measuring 1.7 × 0.8 cm. Head and neck contrast-enhanced computed tomography (CT) revealed an enlarged, non-enhanced oval shape left mandibular mass located superficial to and lying on the left masseter muscle measuring 1.2 cm with foci of calcification; minimal peripheral enhancing components; bilaterally enlarged lymph nodes at IB and IIB levels with the largest preserved fatty hilum on the left IB level measuring 1.1 cm (Figures 1, 2).

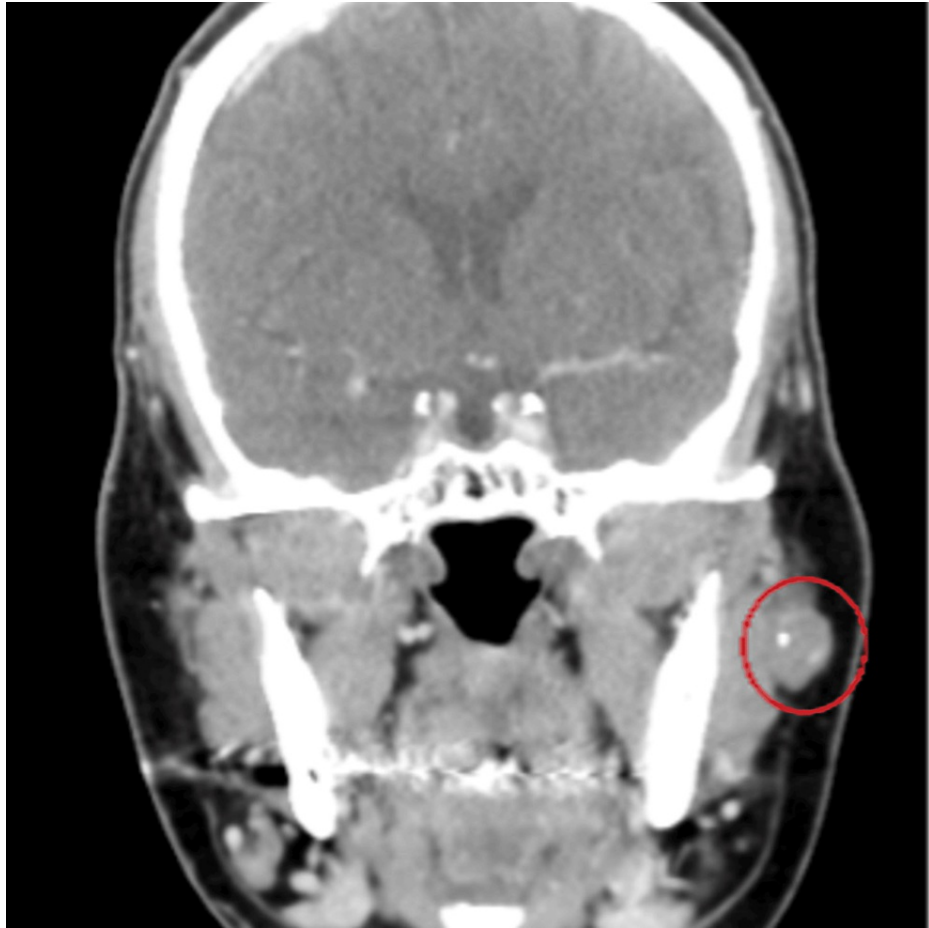
### How to cite this article

Alanazi F M, Alqahtani S, Alruwaili S H, et al. (January 15, 2024) Cavernous Hemangioma in the Parotid Gland of an Adult: A Case Report and Review of Literature. Cureus 16(1): e52285. DOI 10.7759/cureus.52285



**FIGURE 1: CT head and neck (axial section)**

An enlarged, non-enhanced oval shaped left mandibular mass located superficial to and lying on the left masseter muscle measuring 1.2 cm with foci of calcification; minimal peripheral enhancing components.



**FIGURE 2: CT head and neck (coronal section)**

An enlarged, non-enhanced oval shaped left mandibular mass located superficial to and lying on the left masseter muscle measuring 1.2 cm with foci of calcification; minimal peripheral enhancing components.

The patient underwent left superficial parotidectomy and intraoperative frozen section which revealed a cavernous hemangioma without evidence of malignancy. The patient was doing fine postoperatively, with no active complaint, the facial nerve was intact, and the rest of the examination is unremarkable. The patient was followed in the clinic until the wound was healed.

## Discussion

The World Health Organization Classification of Tumors, established in 2005, reported 50 cases of adult hemangiomas globally, highlighting the disorder's rarity [1,7,8]. Cavernous hemangioma is the only parotid hemangioma reported in the literature, with no current data on its incidence in the adult population [9]. Additionally, a recent study by Nagao et al. published a case series of 20 cases of cavernous hemangioma in adult patients and revealed 26 years of age as the mean [10]. Cavernous hemangioma of the parotid gland in adults must be reported because of this unusual discovery.

Cavernous hemangioma of the parotid gland frequently appears as a mass in the parotid region, along with a red-blue macule or papule that may or may not be present and a pulsating sensation when the mass is palpated. However, the case is solely presented as a mass in adults with no apparent relationships. For instance, the usual clinical presentation of patients in multiple case studies was a slowly expanding and asymptomatic mass over the parotid region with no apparent relationships [1,3,11,12].

Salivary gland tumors can be diagnosed using many imaging techniques. An important initial tool is an ultrasound [6,13]. Ultrasound reveals a mass with well-defined borders and either homogenous or heterogeneous echogenicity in cavernous hemangioma cases [14]. However, the sonographic results are not typical. Fine needle aspiration is performed preoperatively in parotid masses, although it is contraindicated in vascular lesions because iatrogenic hematoma may occur [3,6,15]. Magnetic resonance imaging assesses the parotid hemangioma's extension [16,17]. Hemangiomas typically manifest as a well-defined, lobulated, and uniformly enhancing lesion. The lesion is uniformly hypointense on the T1-weighted sequence but hyperintense with varying vascularity on the T2-weighted sequence. Cavernous hemangiomas of the parotid

gland are rarely diagnosed with angiography although this technique is the gold standard for identifying arteriovenous malformations [14,18]. Cavernous hemangioma of the parotid is a rare and unusual tumor that develops in adulthood, making its diagnosis challenging just through clinical examination and imaging methods [6,19].

Adult parotid gland hemangiomas do not regress, thus surgical intervention is required in contrast to infantile hemangiomas that could involute or be treated non-surgically with sclerotherapy, propranolol, intralesional, or systemic corticosteroids [6,20,21]. Preoperative embolization is important for minimizing the size of large hemangiomas, as well as intraoperative bleeding [20]. Non-surgical therapies are only considered in adults if surgery is not an option.

## Conclusions

Cavernous hemangioma in the parotid gland is uncommon in adults. It is difficult to diagnose, thereby necessitating a thorough physical examination and several radiological modalities to improve diagnostic accuracy. This article presents the case of a 66-year-old female Saudi patient with cavernous hemangioma from the diagnosis until the surgical treatment. Nowadays, surgical resection is the most effective interventional treatment for cavernous hemangioma in the parotid gland.

## Additional Information

### Author Contributions

All authors have reviewed the final version to be published and agreed to be accountable for all aspects of the work.

**Concept and design:** Farhan M. Alanazi, Saeed Alqahtani, Sultan H. Alruwaili

**Acquisition, analysis, or interpretation of data:** Farhan M. Alanazi, Saeed Alqahtani, Sultan H. Alruwaili, Abdullah A. Alzamil, Fareed R. AlGhamdi

**Drafting of the manuscript:** Farhan M. Alanazi, Saeed Alqahtani, Sultan H. Alruwaili, Abdullah A. Alzamil, Fareed R. AlGhamdi

**Critical review of the manuscript for important intellectual content:** Farhan M. Alanazi, Saeed Alqahtani, Sultan H. Alruwaili, Abdullah A. Alzamil, Fareed R. AlGhamdi

**Supervision:** Fareed R. AlGhamdi

### Disclosures

**Human subjects:** Consent was obtained or waived by all participants in this study. **Conflicts of interest:** In compliance with the ICMJE uniform disclosure form, all authors declare the following: **Payment/services info:** All authors have declared that no financial support was received from any organization for the submitted work. **Financial relationships:** All authors have declared that they have no financial relationships at present or within the previous three years with any organizations that might have an interest in the submitted work. **Other relationships:** All authors have declared that there are no other relationships or activities that could appear to have influenced the submitted work.

## References

1. Eltohami YI, Suleiman AM, Alrofaey AH: Cavernous haemangioma of the parotid gland in adults: a review of the literature & case report. *Adv Dent Oral Health*. 2018, 1-8.
2. Gampper TJ, Morgan RF: Vascular anomalies: hemangiomas. *Plast Reconstr Surg*. 2002, 110:572-85; quiz 586; discussion 587-8. [10.1097/00006534-200208000-00032](https://doi.org/10.1097/00006534-200208000-00032)
3. Lara-Sánchez H, Peral-Cagigal B, Madrigal-Rubiales B, Verrier-Hernández A: Cavernous hemangioma of the parotid gland in adults. *J Clin Exp Dent*. 2014, 6:e592-4. [10.4317/jced.51750](https://doi.org/10.4317/jced.51750)
4. Childers EL, Furlong MA, Fanburg-Smith JC: Hemangioma of the salivary gland: a study of ten cases of a rarely biopsied/excised lesion. *Ann Diagn Pathol*. 2002, 6:339-44. [10.1053/adpa.2002.36662](https://doi.org/10.1053/adpa.2002.36662)
5. To VS, Chan JY, Tsang RK, Wei WI: Review of salivary gland neoplasms. *ISRN Otolaryngol*. 2012, 2012:872982. [10.5402/2012/872982](https://doi.org/10.5402/2012/872982)
6. Rubina S, Jian G, Yu WX, Singh KK, Fidele NB: A rare case report of parotid cavernous hemangioma in an adult. *J Adv Med Med Res*. 2017, 19:1-5. [10.9754/BJMMR/2017/50899](https://doi.org/10.9754/BJMMR/2017/50899)
7. Thompson L: World Health Organization classification of tumours: pathology and genetics of head and neck tumours. *Ear Nose Throat J*. 2006, 85:74.
8. Pathology and genetics of head and neck tumours (Volume 9) . Barnes, L, Eveson, JW, Sidransky, D, Reichart P (ed): WHO, 2005.
9. Chahine KN, Tohme SM, Chouairy CJ: Cavernous hemangioma of the parotid gland . *J Med Liban*. 2007, 55:165-6.
10. Nagao K, Matsuzaki O, Shigematsu H, Kaneko T, Katoh T, Kitamura T: Histopathologic studies of benign

- infantile hemangioendothelioma of the parotid gland. *Cancer*. 1980, 46:2250-6. [10.1002/1097-0142\(19801115\)46:10<2250::aid-cnrcr2820461023>3.0.co;2-p](https://doi.org/10.1002/1097-0142(19801115)46:10<2250::aid-cnrcr2820461023>3.0.co;2-p)
11. Chen BN: Case report cavernous hemangioma with multiple phleboliths of the parotid gland in adult masquerading assialolithiasis. *Int J Clin Exp Med*. 2017, 10:11097-100.
  12. Huang YT, Ou CY, Lee WT, Hsu HJ: Three cases of parotid hemangiomas in adults . *Ear Nose Throat J*. 2021, 1455613211067834. [10.1177/01455613211067834](https://doi.org/10.1177/01455613211067834)
  13. Choi HJ, Lee YM, Kim JH, Tark MS, Lee JH: Wide excision of accessory parotid gland with anterior approach . *J Craniofac Surg*. 2012, 23:165-8. [10.1097/SCS.0b013e3182413f19](https://doi.org/10.1097/SCS.0b013e3182413f19)
  14. Lai YS, Liu CJ: Cavernous hemangioma of submandibular region with multiple phleboliths-a case report . *Kulak Burun Bogaz Ihtis Derg*. 2016, 27:188-98.
  15. Cho JH, Nam IC, Park JO, Kim MS, Sun DI: Clinical and radiologic features of submandibular triangle hemangioma. *J Craniofac Surg*. 2012, 23:1067-70. [10.1097/SCS.0b013e31824e6cbf](https://doi.org/10.1097/SCS.0b013e31824e6cbf)
  16. Liu J, Cheng LJ, Zhang Y, Song TH, Wang JW: Rich fat hemangioma of the parotid gland in the adult . *J Craniofac Surg*. 2020, 31:1054-5. [10.1097/SCS.0000000000006332](https://doi.org/10.1097/SCS.0000000000006332)
  17. Baker LL, Dillon WP, Hieshima GB, Dowd CF, Frieden IJ: Hemangiomas and vascular malformations of the head and neck: MR characterization. *AJNR Am J Neuroradiol*. 1993, 14:307-14.
  18. Perkins JA, Sidhu M, Manning SC, Ghioni V, Sze R: Three-dimensional CT angiography imaging of vascular tumors of the head and neck. *Int J Pediatr Otorhinolaryngol*. 2005, 69:319-25. [10.1016/j.ijporl.2004.10.008](https://doi.org/10.1016/j.ijporl.2004.10.008)
  19. Jayachandran S, Joshi B: Hemangioma of parotid gland in an adult: an Imaging perspective . *Univ J Surg Surgical Specialities*. 2018, 4:
  20. Plasencia AR, O'Higgins TV: Large parotid and cheek infantile hemangiomas refractory to medical treatment: is there a role for embolization?. *Am J Interv Radiol*. 2020, 4:21. [10.25259/AJIR\\_24\\_2020](https://doi.org/10.25259/AJIR_24_2020)
  21. Righini CA, Berta E, Atallah I: Intramuscular cavernous hemangioma arising from the masseter muscle . *Eur Ann Otorhinolaryngol Head Neck Dis*. 2014, 131:57-9. [10.1016/j.anorl.2013.03.003](https://doi.org/10.1016/j.anorl.2013.03.003)